



## Clinical update

# Combination testing in orthopedic and neurologic physical examination: a proposed model

K. Jeffrey Miller DC<sup>a,\*</sup>, Michael D. Sittler<sup>b</sup>, Denise M. Corricelli<sup>b</sup>,  
Danielle N. DiMura<sup>b</sup>, Jason S. Comerford<sup>b</sup>

<sup>a</sup>Chairman, Department of Clinical Sciences, Cleveland Chiropractic College, Kansas City, MO 64131

<sup>b</sup>Student, Palmer College of Chiropractic-Florida, Port Orange, FL 32129

Received 4 July 2007; received in revised form 8 August 2007; accepted 15 August 2007

### Key indexing terms:

Orthopedics;  
Physical examination;  
Neurologic  
examination;  
Differential diagnosis;  
Chiropractic

### Abstract

**Objective:** This article suggests a 4-part model for teaching and using orthopedic and neurologic physical testing.

**Discussion:** Four methods of combining and sequencing orthopedic and neurologic physical tests are described. The descriptions are followed by examples including test names, test performance, and the relationships between the tests in each group. The principles of the methods originated in the lead author's private practice and were refined while teaching chiropractic students and graduate doctors.

**Conclusion:** This model offers one possible method of combining and sequencing the orthopedic and neurologic examination in an effort to provide a more complete picture portraying the mechanisms, results, pathologies, differential diagnosis, and clinical thought processes associated with common orthopedic and neurologic physical tests.

© 2007 National University of Health Sciences.

## Introduction

Combining orthopedic and neurologic tests is not a new phenomenon. Several authors have described individual combinations.<sup>1-4</sup> This paper goes beyond limited combinations, describing a system that can be

used to form multiple useful combinations. The purpose, as with other descriptions, is to increase the productivity of the physical examination process. Productivity can be increased in multiple ways. Combining tests reduces the number of patient position changes during the examination process. This decreases wear and tear on the patient. The time required for the examination also decreases, and the flow of the examination improves.

Testing combinations and sequences also allow the doctor to gauge the severity of the patient's condition.

\* Corresponding author. Cleveland Chiropractic College, 6401 Rockhill Road, Kansas City, MO 64131, USA. Tel.: +1 913 940 9191.

E-mail address: [kjmdcdabco@yahoo.com](mailto:kjmdcdabco@yahoo.com) (K. J. Miller).

Two physical maneuvers that detect the same pathology are more likely to identify the pathology if performed together than if the tests are performed individually. If the results of 2 tests are positive in combination, but negative individually, the findings can be considered less severe.

The tests described below were selected because they provided good examples of the combination and sequencing methods discussed. They were not selected based on their sensitivity or specificity. Information on sensitivity and specificity is provided where available; but unfortunately, this information is not available for most orthopedic and neurologic tests. Despite the lack of this information, these tests and many others are embedded in health care education and clinical practice. Increasing the utility of the tests until better clinical procedures are available is prudent. The purpose of this article is to offer personal opinions of how orthopedic and neurologic tests may be combined.

## Discussion

### Four methods of test combining

The first method is testing by indirect method. A common example is recording a patient's respiration rate while pretending to record his pulse. This is done to prevent the patient from consciously or subconsciously altering respiration rate. The patient is unaware of the true purpose of the procedure and is deliberately distracted during testing.<sup>5</sup>

The second method of combining applies to tests that have the same mechanism of performance yet test for different pathologies. An example is the combination of the Soto-Hall, Lhermette, Brudzinski, and Lindner tests. The primary mechanism of performance for these tests is flexion of the cervical spine (Table 1). Knowledge of the multiple responses possible with cervical flexion and the positive and negative findings for each test determines how results are interpreted and which test result is listed as positive. The movement of a joint or series of joints affects multiple tissues. Bones,

cartilage, muscles, tendons, ligaments, fascia, blood vessels, nerves, skin, and other tissues are involved in or influenced by a movement. It is almost impossible to consider an individual physical maneuver as testing a single tissue or pathology. True differential diagnosis occurs when the examiner understands the maneuver's effect on every tissue influenced and the possible patient response generated by each if pathological or dysfunctional.

The third method of combination testing involves tests that identify the same pathology but have different mechanisms of performance. An example is the combination of the Lindner, straight leg raising, and Bragard tests (Table 2). The mechanisms of performance for these tests differ, but they all test for lower extremity radicular pathology. Combining these tests requires performing all 3 mechanisms (cervical flexion, straight leg raising, and foot dorsiflexion) simultaneously in an attempt to reproduce radicular symptoms. This is the method of combined testing that allows the severity of the patient's condition to be gauged. If all 3 tests are required to reproduce symptoms, the patient's condition is not as severe as it would be if symptoms were reproduced by 2 tests in combination or if the tests produced symptoms individually.

The fourth method is sequential testing or using testing groups. It is almost impossible for some orthopedic and neurologic tests to stand alone in the diagnostic process. Few tests are absolute indicators of the pathology they are intended to detect, and many of the tests raise more questions than they answer.

Grouping related tests in sequence provides clinical information needed to clarify test findings. Tests with higher specificity and sensitivity require smaller sequences. Tests with lower specificity and sensitivity require larger sequences.

### Testing by the indirect method

Range of motion (ROM) can be tested by the indirect method. Range of motion testing has long been a standard assessment of the musculoskeletal system. This is despite the subjectivity of the methods and

**Table 1** Cervical flexion tests

Test	Major Mechanism	Positive Indicators	Pathology
Soto-Hall	Cervical Flexion	Cervical and/or Thoracic Pain	Spinal Sprain, Strain, Subluxation, or Fracture
Lhermitte	Cervical Flexion	Shock or Electric Sensation in the Extremity(s)	Spinal Cord Pathology
Brudzinski	Cervical Flexion	Spine Pain and/or Knee and Hip Flexion	Meningeal Irritation
Lindner	Cervical Flexion	Lower Extremity Radicular Pain	Radiculopathy

**Table 2** Same pathology/different mechanism

Test	Major Mechanism	Positive Indicators	Pathology
Lindner	Cervical Flexion	Lower Extremity Radicular Pain	Radiculopathy
Straight Leg Raise	Flexing the Hip by Lifting the Straight Leg	Lower Extremity Radicular Pain	Radiculopathy
Bragard	Dorsiflexion of the Foot	Lower Extremity Radicular Pain	Radiculopathy

findings. Range of motion testing has not been reliable between different methods of testing or between examiners.<sup>6</sup> These findings are complicated by patients who can limit their ROM in situations where pain may limit their motion or possibly when personal gain is a motivating factor. Subjectivity of methods and patient motives played a role in the worker’s compensation environment moving toward diagnostic-related estimates and away from ROM as the primary method of assessment in impairment rating.<sup>7</sup>

The Soto-Hall test for cervicothoracic sprain, strain, or fracture uses cervical flexion. The Hautant test for vertebral artery compromise uses cervical extension and rotation in combination. Shoulder depressor test for brachial plexus pathology begins with lateral bending of the cervical spine before depressing the shoulder. The slump test for neuromeningeal tract tension is performed in 5 steps. Lumbosacral flexion, cervical flexion, knee extension, foot dorsiflexion, and cervical extension are performed in sequence. The Kemp test uses lumbar extension and lateral bending. The Schepelmann test involves lumbosacral lateral bending (Table 3).

Observation of ROM during orthopedic and neurologic testing is assisted by patient distraction. Procedures and their associated questions cause the patient to be unaware that his degree of movement is also being assessed.<sup>8,9</sup> Personal gain is then decreased as one of the factors influencing examination outcome during testing. This method also increases examination efficiency by obtaining maximum information in the shortest amount of time. In addition, each ROM may be observed multiple times during a single examination.

**Same mechanism/different pathology**

The following series of tests are all performed standing and require close supervision by the examiner to ensure stability and safety of the patient. All tests are typically performed bilaterally, beginning with the asymptomatic side.

The Trendelenburg test is performed by the patient standing on one leg. Contraction of the gluteus medius muscle on the side of weight bearing normally causes the pelvis to elevate on the non–weight-bearing side. If

the pelvis fails to elevate or sags, the result of the test is positive, indicating that the gluteus medius is weak on the side of weight bearing.<sup>10</sup> The result of this test may also be positive in some hip pathologies.<sup>11</sup>

The one-legged standing lumbar extension test is performed by the patient standing on one leg. The lumbar spine is then extended. The testing position increases pressure at the pars interarticularis on the side of weight bearing. Lumbar pain on the weight-bearing side is attributed to pars fracture (spondylolysis or spondylolisthesis).<sup>12-14</sup>

The stork test is performed by the patient standing on one leg with the lumbar spine extended. This procedure tests proprioception and stability of the sacroiliac, knee, ankle, and foot joints. The patient’s posture, balance, and control over conscious movement are also assessed. The stork test is also known as the *one-legged stance*. The inability to maintain the position for 10 seconds indicates a problem with one of the functions/regions listed above.<sup>12</sup> The stork test can also be performed with the patient’s eyes closed. This intensifies the assessment of proprioception and assesses the labyrinthine systems in the absence of visual input. A positive finding is the patient’s inability to stand with little or no body motion for 10 seconds.<sup>12</sup>

The flamingo test is performed by the patient standing on one leg and hopping up and down at least 3 times. Increased pain in the hip, sacroiliac, and/or symphysis pubis articulations are positive signs indicating nonspecific pathologies of these articulations.<sup>15</sup>

The strength (motor) test for the gastrocnemius and soleus muscles recommended by Hoppenfeld<sup>10</sup> is performed by the patient hopping up and down on

**Table 3** Spinal ranges of motion replicated during orthopedic and neurologic tests

Range of Motion	Tests That Use the Range
Cervical Flexion	Soto-Hall, Slump
Cervical Extension	Hautant, Slump
Cervical Lateral Bending	Shoulder Depressor
Cervical Rotation	Hautant
Lumbosacral Flexion	Slump Test
Lumbosacral Extension	Kemp
Lumbosacral Lateral Bending	Schepelmann, Kemp

one foot several times. The patient should be able to propel his body weight into the air and land on the toes and forefoot. The test may be a general neurologic test, or the patient may have a symptomatic side. A positive indication is the inability to jump or landing flat-footed. Patient's inability to perform the test may be due to weak gastrocnemius or soleus muscles and/or Achilles tendon pathology.

The heel drop test is performed by the patient raising up on the toes then suddenly dropping onto the heels. The force of the body weight landing on the heels jars several internal organs. Flank pain resulting from the heel drop test indicates kidney pathology. DeGowin et al <sup>16</sup> recommends this test for identifying lumbar pain due to spondylitis. The Hoppenfeld and flamingo maneuvers reproduce this mechanism.

The above tests are similar in performance. Their differences lie primarily in the location of pain or dysfunction. Their similarities and differences are detailed in Table 4. With this in mind, practical use of these tests in combination involves the patient standing on one leg and balancing for a few seconds with lumbar extension and the eyes closed. Lumbar extension can then be reduced, the eyes opened, and the patient instructed to jump up and down at least 3 times (Fig 1).

The examiner observes the patient for dysfunction and signs of pain. The examiner also questions the patient about common locations of pain associated with the various tests. Results are attributed to the appropriate test and recorded. Unfamiliar results to the examiner should

be noted during combined procedures. They are not positive findings; however, they may be clinically significant. Further investigation is warranted in these situations to avoid misdiagnosis and/or mistreatment.

**Different mechanism/same pathology**

The Beevor sign, Milgram test, and Dejerine test are tests commonly used by spine care practitioners to detect space-occupying lesions and general spinal pathology.

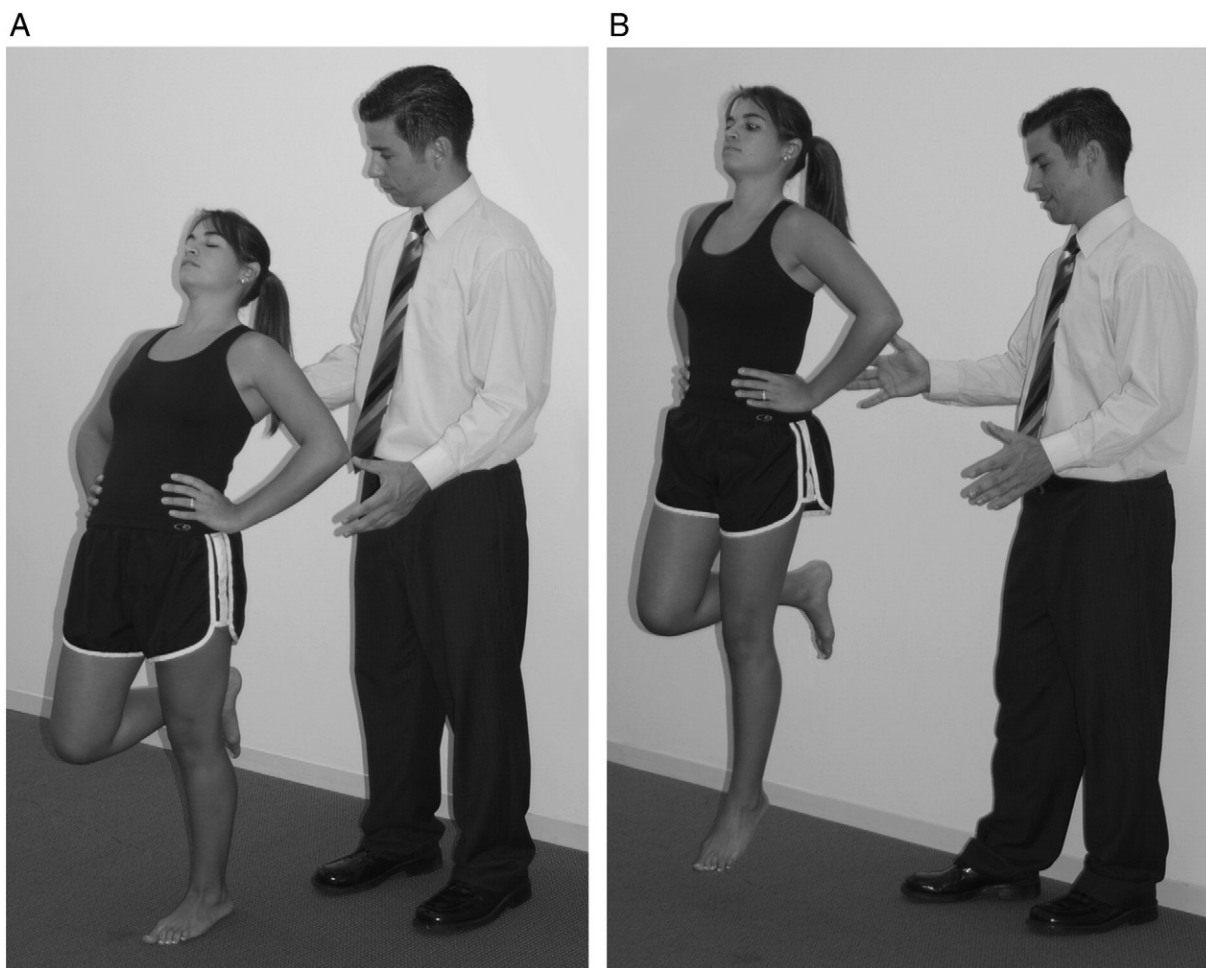
To elicit the Beevor sign, the supine patient performs a partial sit-up or a partial bilateral leg lift while the examiner observes and/or palpates the umbilicus. The umbilicus should not move during either maneuver. A positive sign occurs when the umbilicus moves superior, inferior, left, or right. The umbilicus moves toward the stronger abdominal muscles and away from weak abdominal muscles. This indicates motor dysfunction associated with the thoracic region. The maneuvers also increase pressure in the thecal sac containing the spinal cord.<sup>17,18</sup>

In the Milgram test, the supine patient performs a partial bilateral leg lift that is held 6 in above the table for 15 to 30 seconds. This replicates the bilateral leg lift of the Beevor sign. A positive test result occurs when the patient experiences lumbosacral pain indicating unspecified lumbosacral pathology. Intrathecal pressure is increased in the Milgram test as in the Beevor sign.<sup>18</sup>

**Table 4** Simultaneous testing, same mechanism/different pathology

Test	Performance	Positive Indicators	Possible Pathology
Flamingo Test	Hop Up and Down on 1 leg	Pain in Hip/SI Joint	SI Articulation and Symphysis Pubis Articulation
1-Legged Standing Lumbar Extension Test	Stand on 1 Leg and Extend the Lumbar Spine	Pain in the Lumbar Spine	Spondylolysis or Spondylolisthesis
Hoppenfeld Gastrocnemius and Soleus Test	Jump on 1 Leg and Land on the Toes	Unable to Jump and/or Lands Flat-Footed	Weak Gastrocnemius and Soleus Muscles and/or Torn Achilles Tendon
Stork Test	Balance on 1 Leg and Extend the Lumbar Spine	Pain in SI, Knee, Ankle, or Foot Joints; Loss of Balance	SI, Knee, Ankle, or Foot Joint Instabilities; Proprioceptive Indications; UMN
1-Legged Stance With Eyes Open	With Eyes Open, Stand on 1 Leg, Raise Opposite Leg Off Floor Until Ankle Is Parallel With Knee	Patient Is Unable to Stand Without Excessive Movement for 10 s	Sensorimotor Response Indication, UMN Problem
1-Legged Stance With Eyes Closed	With Eyes Closed, Stand on 1 Leg, Raise Opposite Leg Off Floor Until Ankle Is Parallel With Knee	Patient Is Unable to Stand Without Excessive Movement for 10 s	Proprioceptive and Labyrinthine Systems Inadequacy
Heel Drop	Dropping Body Weight Onto the Heels	Flank Pain in the Area of the Kidney(s)	Kidney Pathology

SI, Sacroiliac; UMN, upper motor neuron.



**Fig 1.** A, Combination of the Trendelenburg test, one-legged standing test, and stork test. B, Combination of the flamingo test, Hoppenfeld test, and heel drop sign.

The Dejerine triad is accomplished by the patient performing one or more of 3 separate maneuvers (Table 5). The triad includes Valsalva maneuver (performed by holding the breath and bearing down as though having a bowel movement), coughing, and sneezing. Spine and/or extremity pain is a positive finding indicating the possibility of a space-occupying lesion associated with the thecal sac. Intrathecal pressure is increased in the Dejerine triad as in the Beevor and Milgram tests.<sup>18</sup> Practical combining of these tests involves instructing the supine patient to

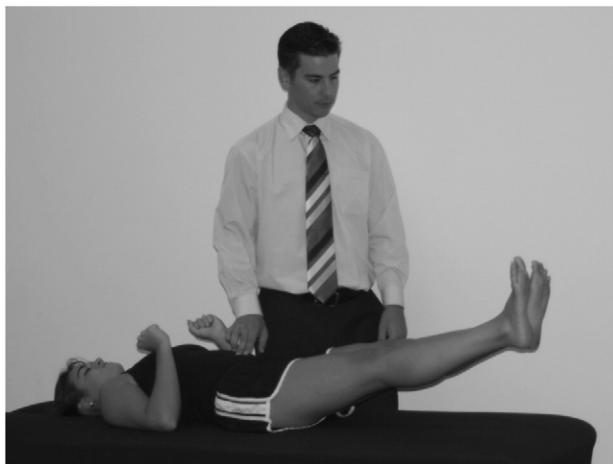perform a bilateral leg lift while holding the breath and bearing down for 15 to 30 seconds. This is accomplished while the examiner palpates/observes the umbilicus and questions the patient about the location of any pain (Fig 2).

**Sequential testing**

The Hautant test is performed by the seated patient flexing the shoulders 90° and placing the arms in the anterior plane with the elbows extended and the hands

**Table 5** Simultaneous testing, different mechanism/same pathology

Test	Performance	Positive Indicators	Possible Pathology
Beevor Sign	The Patient Performs a Partial Sit-Up or Bilateral Leg Raise	The Umbilicus Moves From Its Central Position	Thoracic Motor Dysfunction, the Umbilicus Moves Away From the Side of Weakness
Milgram Test	The Patient Performs a Bilateral Leg Raise	Generalized Lower Back Pain	A Variety of Lumbar Pathologies May Be Present
Dejerine Triad	The Patient Coughs or Sneezes or Bares Down While Holding the Breath	Head, Spinal, and/or Extremity Pain	A Space-Occupying Lesion Is Suspected



**Fig 2.** Combination of the Beevor test, Milgram test, and Dejerine test/Valsalva maneuver.

supinated. The examiner then guides the patient's head and neck into extension and rotation with the eyes closed. The testing position is held for 15 to 30 seconds and repeated on the opposite side. The eyes are closed to prevent the patient from compensating for abnormal arm movements. The result of the test is positive if one of the patient's hands pronates or an arm drops (drifts) from the testing position. Positive findings indicate vascular compromise of the vertebral arteries. Head/cervical extension and rotation partially occlude the vertebral arteries, which in turn would reduce blood flow in the cortex and/or cerebellum. If other vessels (the carotid arteries) cannot compensate for decreased blood flow in the vertebral arteries, arm movement occurs.<sup>19</sup> Additional positive findings for the Hautant test may include dizziness, vertigo, nystagmus, or

blurred vision. These symptoms are frequently associated with vertebral artery compromise, but many of them (dizziness, vertigo, and nystagmus) may also be attributed to vestibular problems (Table 6).

Sequencing of the Hautant test with other tests for vertebral artery function and other tests that may produce dizziness, vertigo, nystagmus, and blurred vision is necessary. Cote et al<sup>20</sup> found cervical extension and rotation to have zero sensitivity and 67% to 90% specificity in evaluating vertebral artery flow. Low sensitivity solidifies the need to differentiate between vertebral artery and vestibular problems.

The drift test is performed by the seated patient flexing the shoulders 90° and placing the arms into the anterior plane with the elbows extended and the hands supinated. The cervical spine and head are held in the neutral position. The patient holds this position for 15 to 30 seconds with the eyes closed. The eyes are closed to prevent the patient from compensating for abnormal arm movements. The result of the test is positive if one of the patient's hands pronates or an arm drops (drifts) from the testing position. Positive findings indicate that the cortex and/or cerebellum is dysfunctional.<sup>21</sup> The presence of a lesion can be detected by the test, but the type of lesion cannot.<sup>22</sup>

The similarities between the Hautant and drift tests allow them to be combined and performed simultaneously. The combination occurs simply by performing the Hautant test. If the result of the Hautant test is negative bilaterally, that of drift is also negative. Drift is not dependent upon head position, so there is no need to perform drift separately. When the result of the Hautant test is positive, drift should be performed separately as described with the head in the neutral

**Table 6** Sequential testing

Test	Performance	Positive Indication	Possible Pathology
Hautant Test	Head Rotation and Extension With the Eyes Closed and the Arms Extended Into the Anterior Plane	The Patient's Hand Pronates or an Arm Drops or Drifts From the Testing Position; Dizziness, Vertigo, Nystagmus, or Blurred Vision Is Also Possible	Vascular Compromise of Vertebral Arteries With Inadequate Compensation From Other Vessels
Drift Test	The Arms Are Extended Into the Anterior Plane With the Eyes Closed and the Head in Neutral	The Patient's Hand Pronates or an Arm Drops or Drifts From the Testing Position	Motor Cortex or Brain Stem Dysfunction
Arm Rolling	The Arms Are Placed Parallel With the Elbows Flexed and Then Rotated Around Each Other	One Arm Remains Stationary While the Other Arm Rotates Around It	Motor Cortex or Brain Stem Dysfunction on Opposite Side of Stationary Arm
Dizziness Test	The Head Remains Stationary While the Patient's Lower Cervical Spine Is Rotated by the Examiner Using the Shoulders as Leverage	Dizziness, Vertigo, Nystagmus, or Blurred Vision	Vertebral Artery Compromise

position. When the result of the Hautant test is positive and that of drift is negative, vascular compromise is indicated. If the results of both tests are positive, then an existing lesion affecting the motor cortex and/or cerebellum is suspected.<sup>23</sup>

The dizziness test is performed to confirm a positive Hautant test result and differentiate vascular compromise from vestibular pathology. This is necessary to differentiate vascular-induced symptoms associated with vertebral artery compromise and vestibular-induced symptoms triggered by movement of the head. The dizziness test is performed with the patient seated looking forward. The examiner rotates the patient's shoulders in opposite directions (one forward and one backward). The patient looks forward throughout the test, and the head must not

move. The maneuver is easier to perform if the patient is seated on an examination stool that rotates. The cervical spine rotates from the bottom up during the maneuver while the head remains stationary. The rotated shoulder position is held for 15 to 30 seconds and then repeated by rotating the shoulders in the opposite direction.<sup>19</sup> Positive results are dizziness, vertigo, nystagmus, or blurred vision. If symptoms are present (in the absence of head movement), they confirm vertebral artery compromise and temporary cortical/brain stem ischemia. A negative result is a lack of symptoms. Negative results indicate signs and symptoms during the Hautant test may be from vestibular dysfunction triggered by head movement. Testing of the eighth cranial nerve and vestibular apparatus is indicated after a negative result.

A



B



C



**Fig 3.** A, Combination of the Hautant test and drift test. B, Dizziness test. C, Arm rolling test.

The arm rolling test is performed to confirm a positive drift test result. The seated patient flexes and internally rotates the shoulders. The elbows are then flexed, placing the forearms parallel to each other. The patient is then instructed to rotate the forearms around each other for 5 to 10 seconds in one direction and then in reverse directions. The result of the test is positive if one arm remains stationary while the other arm rotates around it. A motor lesion (cortex) is indicated on the opposite side of the stationary arm.<sup>24</sup> Another version of this test, the finger rolling test, involves rolling the index fingers around each other. Finger rolling requires finer motor control. Clinical observations indicate this test may be more sensitive than arm rolling.<sup>25</sup>

It should be obvious from the descriptions of the Hautant, drift, dizziness, and arm rolling tests that they have limitations individually. Sequencing these tests provides the examiner with useful diagnostic information for differentiating vertebral artery, motor cortex, cerebellar, and vestibular pathologies (Fig 3).

### Interpretation

When a combination or sequence fails to produce positive findings for any of the tests included, all of the test results are considered negative. The examiner can proceed to additional tests and procedures. When a positive finding for a test within a combination or sequence does occur, the examiner should then perform that test and other tests individually to confirm the result. The exception here may be the tests with the same mechanism that test for different pathologies.

Responses during combinations and sequences that are not positive indicators for any of the tests should not be recorded as positive results. Attempts to identify the source of atypical findings should be made. Differential diagnosis requires this to determine if the findings are clinically significant.

### Conclusion

For decades, orthopedic and neurologic tests have been listed by region, alphabetical order, or pathology. Regional and alphabetical organization provides quick access when a clinician needs to refresh his memory of a specific test; however, this is one of the few benefits of this arrangement. Traditional organizational methods are like disconnected puzzle pieces and may not provide as much information when observed separately. The model presented in this article offers one possible method of combining and sequencing the

pieces of the puzzle in an effort to move toward completion of the picture portraying the mechanisms, results, pathologies, differential diagnosis, and clinical thought processes associated with common orthopedic and neurologic physical tests.

### References

1. Cox JM. In: Low back pain, mechanism, diagnosis and treatment. 6th ed. Philadelphia: Lippincott Williams and Wilkins; 1999. p. 424, 430.
2. Riley BM. Practical strategies in outpatient medicine. Philadelphia: WB Saunders Company; 1984. p. 12.
3. Breig A, Troup JD. Biomechanical considerations in the straight-leg-raising test. Cadaveric and clinical studies of the effects of medial hip rotation. *Spine* 1979;4(3):242-50.
4. Maitland GD. The slump test: examination and treatment. *Aust J Physiother* 1985;31(6):215-9.
5. Jarvis C. Physical examination and health assessment. 4th ed. St Louis: Saunders; 2004. p. 182.
6. Souza TA. Which orthopedic tests are really necessary? In: Lawrence DJ, Cassidy JD, McGregor M, et al, editors. *Advances in chiropractic*. St Louis (Mo): Mosby-Year Book; 1994. p. 101-58.
7. American Medical Association. In: *Guides to the evaluation of permanent impairment*. 5th ed. Chicago: AMA; 2001. p. 373-4, 398.
8. Miller KJ. The slump test: clinical applications and interpretations. *Chiropr Tech* 1999;11(4):157-63.
9. Miller KJ. Range of motion testing: a fresh look. *J Am Chiropr Assoc* 2003;40(10):42-5.
10. Hoppenfeld S. In: *Physical examination of the spine and extremities*. Norwalk: Appleton-Century-Crofts; 1976. p. 164, 229.
11. Bronson WE. The pediatric hip. *Curr Opin Orthop* 2001;12(6):470-9.
12. Morris CE. *Low back syndromes*. New York: McGraw-Hill; 2006. p. 442.
13. Lim MR, Yoon SC, Green DW. Symptomatic spondylolysis: diagnosis and treatment. *Curr Opin Pediatr* 2004;16(1):37-46.
14. Maschi L, Pike J, Malara F, Phillips B, Bennell K, Brukner P. Use of the one-legged hyperextension test and magnetic resonance imaging in the diagnosis of active spondylolysis. *Br J Sports Med* 2006;40:940-6.
15. Cipriano JJ. *Photographic manual of regional orthopaedic and neurological tests*. 4th ed. Philadelphia: Lippincott Williams & Wilkins; 2003. p. 324.
16. DeGowin RL, LeBlond RF, Brown DD. *DeGowin's diagnostic examination*. 8th ed. New York: McGraw-Hill; 2004. p. 551.
17. Villavicencio AT, Dinitrov DE, McGirt MJ, Turner DA. Management of acute cervical spinal cord injury. *Neurologist* 2001;7(5):287-97.
18. Evans RC. In: *Illustrated orthopedic physical assessment*. 2nd ed. St. Louis: Mosby; 2001. p. 436-7, 574-5, 82-3.
19. McGee DJ. *Orthopedic physical assessment*. 4th ed. St Louis: Saunders/Elsevier; 2006. p. 154-6.
20. Cote P, Kreitz BG, Cassidy D, Thiel H. The validity of the extension-rotation test as a clinical screening procedure before neck manipulation: a secondary analysis. *J Manipulative Physiol Ther* 1996;19(3):159-64.



21. Weaver DF. A clinical examination technique for mild upper motor neuron paresis of the arm. *Neurology* 2000;54(2): 531-3.
22. Goldberg S. The four-minute neurological exam. Miami: Medmaster; 1988. p. 34-5.
23. Miller KJ. Hautant's test. *J Am Chiropr Assoc* 2004;40(2):44-7.
24. Dejong WW. The neurologic examination. 6th ed. Philadelphia: Lippincott Williams & Wilkins; 2005. p. 393.
25. Yamamoto T. Forearm-rolling test. *Neurology* 1995;45(12): 2299.